

A Study of Pharmacokinetics of Sodium Thiopental in Rats by Histological Examination of Kidney and Heart

Kataria Srishti¹, Mehra Lalita² and Badiye Ashish³

¹Institute of Forensic Science, Mumbai University, Mumbai, INDIA

²Department of Nuclear Medicine and Allied Sciences (iNMAS), DRDO, Timarpur, Delhi, INDIA

³Institute of Forensic Science (Govt. of Maharashtra), RTM Nagpur, University, Nagpur, INDIA

Available online at: www.isca.in

Received 19th September 2012, revised 29th September 2012, accepted 1st October 2012

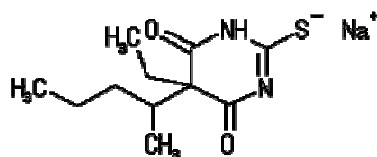
Abstract

Sodium thiopental, better known as sodium pentothal, thiopentone sodium, or trapanal, is a rapid-onset short-acting barbiturate general anaesthetic. It is an intravenous ultra-short-acting barbiturate. Sodium thiopental is a depressant and is sometimes used during interrogations—not to cause pain, but to weaken the resolve of the subject and make him or her more compliant to pressure. In the recent times narco-analysis was gaining momentum when most cases were being investigated using it as a major guiding tool. But in the year 2010 the Supreme Court of India ruling stated that Narco-analysis can be a part of the investigation but not the sole criteria for the conviction of the accused. This paper therefore studied the effects of sodium thiopental in albino rats to check for any damages that occurred at histological levels. Not only is narco-analysis a technique that doesn't produce results that are reproducible and consistent, also it is a technique that causes harm.

Keywords: Truth serum, effects of sodium thiopental, narco-analysis.

Introduction

Barbiturates are a class of drugs that act on the GABA_A receptor in the brain and spinal cord. The GABA_A receptor is an inhibitory channel that decreases neuronal activity, and barbiturates enhance the inhibitory action of the GABA_A receptor. Barbiturates, benzodiazepines, and alcohol all bind to the GABA_A receptor¹. Barbiturates that act on the barbiturate binding site of the GABA_A receptor directly gate the chloride ion channel of the GABA_A receptor, whereas benzodiazepines acting on the benzodiazepine site on the GABA_A receptor increase the opening frequency of the chloride ion channel. Doses of barbiturates may be lethal. Barbiturates can activate GABA receptors in the absence of the GABA molecule, whereas benzodiazepines need GABA to be present to have an effect: this may explain the more widespread effects of barbiturates in the central nervous system. Barbiturates have anaesthetic, sedative, anxiolytic, anticonvulsant and hypnotic properties (anesthesia and analgesia)



Thiopental Sodium

Figure-1

Structure of Sodium thiopental

Metabolism: As with all lipid soluble anaesthetic drugs, the short duration of action of sodium thio-pentothal is almost

entirely due to its redistribution away from central circulation towards muscle and fat tissue². Once redistributed the free fraction in the blood is metabolized in the liver. Sodium thiopental is mainly metabolized to pentobarbital, 5-ethyl-5-(1'-methyl-3'-hydroxybutyl)-2-thiobarbituric acid, and 5-ethyl-5-(1'-methyl-3'-carboxypropyl)-2-thiobarbituric acid³. The usual dose range for induction of anaesthesia using thiopental is from 3 to 7 mg/kg; however, there are many factors that can alter this. As with nearly all anaesthetic drugs, thiopental causes cardiovascular and respiratory depression resulting in hypotension, apnoea and airway obstruction. Side effects include headache, emergence delirium, prolonged somnolence and nausea. Intravenous administration of sodium thiopental is followed instantly by an odour sensation, sometimes described as being similar to rotting onions. The hangover effects may last up to 36 hours. Although molecules of thiopental contain one sulfur atom, it is not a sulfonamide, and does not show allergic reactions of sulfa/sulpha drugs.

Material and Methods

Albino rats have served as an important animal model for research in psychology, medicine, and other fields. Drug sodium thiopental was weighed in doses and dissolved in physiological saline for administering to the rats with the use of a syringe.

Analysis Procedure: Administration of Drug: RAT 1: The rat was weighed and was found to be 171 gms. A dose of 0.3 mg

was weighed and dissolved in 1 ml physiological saline. The dose was administered with the help of a syringe intraperitoneally over a period of 5 minutes. The dose was gradually increased to 0.7 mg over a period of 7 weeks. The rat was then dissected. Heart and kidneys were removed and placed in Bouin's fluid.

RAT 2: The rat was weighed and was found to be 239 gms. A dose of 0.5 mg was weighed and dissolved in 1 ml physiological saline. The dose was administered with the help of a syringe intraperitoneally over a period of 5 minutes. The dose was gradually increased to 0.9 mg over a period of 7 weeks. The rat was then dissected. Heart and kidneys were removed and placed in Bouin's fluid.

Rat Dissection: The rat was held with forefinger and thumb encircling the head so that the ends of the forefinger and thumb were beneath the back edges of the rat's lower jaw. One hind limb was secured between two fingers. The rat was placed in a desiccator with 2 ml chloroform in it (anaesthesia).

The rat was stretched out in the supine position in the dissection tray. Pins were used to secure the rat on the tray. A midline incision was made through the skin from the pubic region to the tip of the lower jaw. A midline incision was made through the abdominal wall musculature from the pubic symphysis to the lower edge of the sternum. Bleeding was minimal in the midline cut.

The rib cage was cut open with the help of a pair of scissors. Kidneys were removed and placed on a watch glass with distilled water to avoid drying.

The heart was also placed on a watch glass with distilled water. The organs were treated further to prepare blocks for microtomy.

Preparation of Blocks for Microtomy: i. The tissue was placed in Bouin's solution. Bouin's solution acts as a fixative. The tissue becomes hard and hardening further resists post mortem changes. Fixative coagulates and renders insoluble the elements of tissues which may not be dissolved in further processing. The fixative agent renders insoluble the various constituents of cells, alters their refractive index and thus makes them optically differentiated under the microscope. The tissue was cut in square shape and placed in labelled vials in Bouin's solution for 24 hours. ii. After the fixation was completed the fixative was poured out and distilled water was added to the tube containing material. Material was washed several times with distilled water. a pinch of lithium carbonate was added to quicken the washings. The presence of fixative agent in tissues or cells inhibits good staining. iii. Dehydration was completed in the same tube starting with 30%, 70%, 90%. iv. Clearing tissue- alcohol was poured out and methyl benzoate was added. It was left for 24 hours. v. Preparation of tissue for embedding- methyl benzoate was removed and cleaned. The tissue was then

ready for embedding. vi. Paraffin infiltration and embedding- the wax was melted in an oven set at 62°C. The wax was filtered. The tissue was placed in a series of infiltration cups filled with melted wax before embedding. vii. The wax was poured in an l shaped mould and the tissue was placed in it. viii. The block was allowed to set completely. ix. Trimming of block- a good scalpel was used to remove the extra wax from the block. wax was scrapped off leaving 5-8 mm wax behind the tissue with the tissue slightly visible. x. Mounting of the block on the block holder- 1 mm of wax was spread on the round block holder and a small cavity was made in the centre of the wax. The tissue was placed in the cavity and fixed there by pressing with a slightly warm scalpel. xi. The block holders along with the block were immersed in cold water in a beaker for 20-30 minutes. xii. The block holder was then mounted on the microtome for section cutting.

Cutting of Ribbons: The angle of the knife was adjusted and the thickness for the ribbons was set. On rotating the drive wheel thin sections were obtained. The ribbon was placed on a slide and washed with warm distilled water to remove the wax. It was air dried. Mayer's albumin was spread evenly on the slide with a finger and the tissue was fixed. The slides were then stained

Staining: The stain used was Haematoxylin delafield. The staining time was 2 minutes after which the sections were washed with an upgrade of alcohols to remove excess stain and for better visibility.

Mounting: The tissue was kept over a glass slide in a drop of DPX mounting and cover slip was lowered slightly. The slide was kept in the hot air oven for drying.

Micrograph: The slides were first viewed under 10 X and focused. Then they were viewed under 40 X. Target area on the tissue was identified and photographed using Olympus 12 megapixel digital SLR. The images were stored digitally and observed.

Result and Discussion

RAT 1: The albino rat taken as control was a male of 6 weeks and weighed 171 gms. No drug dose was administered and heart and kidneys were retrieved to be compared to the treated samples.

RAT 2: Day 0 – The weight of the male Albino Rat 2 on day 0 before administering the drug was observed to be 171 gms. Following are the observation post administration of the drug Sodium Thiopental:

RAT 3: Day 0 – The weight of the male Albino Rat 3 on day 0 before administering the drug was observed to be 239 gms. Following are the observation post administration of the drug sodium thiopental:

Table-1
Observation Table showing day, weight, dosage, and observation made for Rat 2.

S.No.	DAY	WEIGHT(gm)	DOSE(mg)	OBSERVATION
1.	1	171	0.3	-regained normal activity soon after dosage. -drinking water. -avoiding food. -little discoloration in fur observable. -diet back to normal within 30 minutes
2.	4	171	0.3	-not much decrease in movement after dosage. -drinking water. -diet normal
3.	8	169	0.3	-Slowed movements. -drinking water. -regained normal activity within 5 minutes. -diet normal
4.	11	163.9	0.3	-Slowed movements. -drinking water. -regained normal activity within 5 minutes. -diet normal.
5.	15	168	0.5	-Slowed movements. -drinking water. -regained normal activity within 10 minutes. -diet normal.
6.	18	177	0.5	-Slowed movements. -drinking water. -regained normal activity within 5 minutes.
7.	30	180	0.5	-Slowed movements. -drinking water. -regained normal activity within 5 minutes.
8.	33	183.5	0.5	-Slowed movements. -drinking water. -regained normal activity within 5 minutes.
9.	36	189	0.7	-Slowed movements. -drinking water. -regained normal activity within 15 minutes.
10.	39	192	0.7	-Slowed movements. -drinking water. -regained normal activity within 15 minutes.
11.	41	207	0.7	-Slowed movements. -drinking water. -regained normal activity within 15 minutes.

Table-2
Observation Table showing date, weight, dosage, and observation made for Rat 2

S.No.	DAY	WEIGHT(gm)	DOSE(mg)	OBSERVATION
1.	1.	239	0.5	-Slowed movements. -drinking water. -regained normal activity within 20 minutes.
2.	4.	250	0.5	-Slowed movements. -drinking water. -regained normal activity within 5 minutes.
3.	8	229	0.5	Slowed movements. -drinking water. -regained normal activity within 5 minutes. -lesions behind right ear. Fig. 1
4.	11	227	0.7	-Slowed movements. -drinking water. -regained normal activity within 5 minutes. -open lesion on neck.
5.	15	218	0.7	-Slowed movements. -drinking water. -regained normal activity within 10 minutes. -small lesion on left cheek.
6.	18	232.50	0.7	-Slowed movements. -drinking water. -regained normal activity within 5 minutes. -small lesions observed on the back. Fig. 2
7.	30	250	0.9	-Slowed movements. -drinking water. -regained normal activity within 5 minutes. -lesions increased in number.
8.	33	257	0.9	-Slowed movements. -drinking water. -regained normal activity within 5 minutes. -lesions bleed on handling the rat.

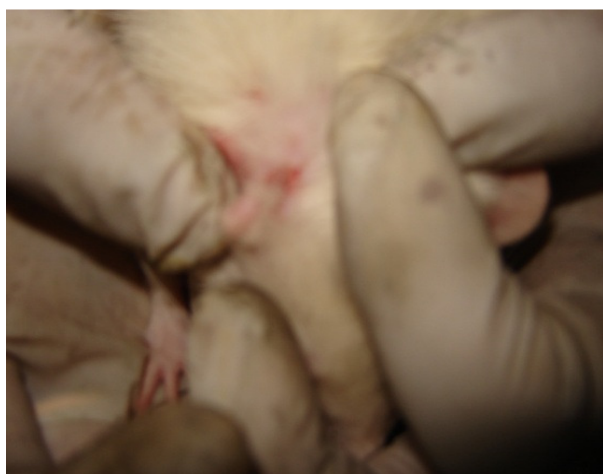

Figure-1
Lesions behind right ear

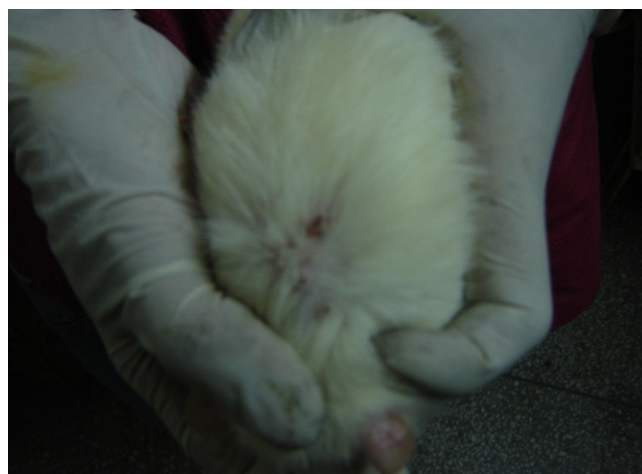


Figure- 2
Lesions on back

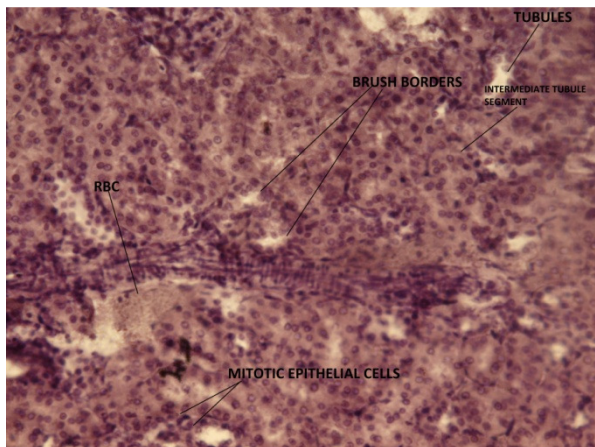


Figure-3
Kidney Control Sample

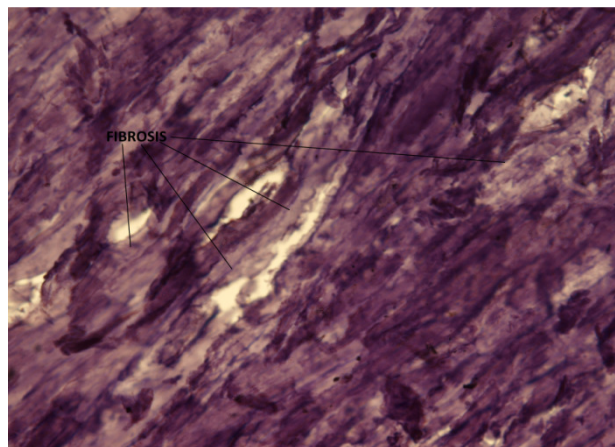


Figure-6
Heart Sample 0.9

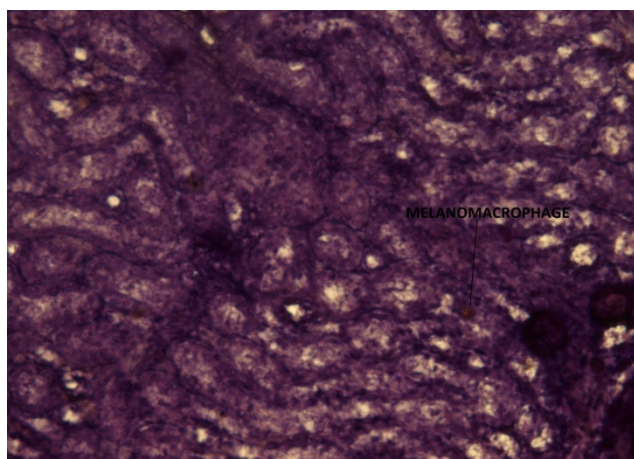


Figure-4
Kidney Sample 0.9




Figure-7
Heart Sample 0.9

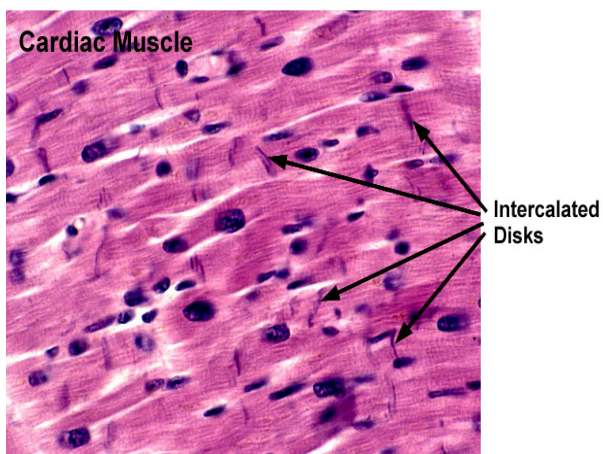

Figure-5
Heart Control

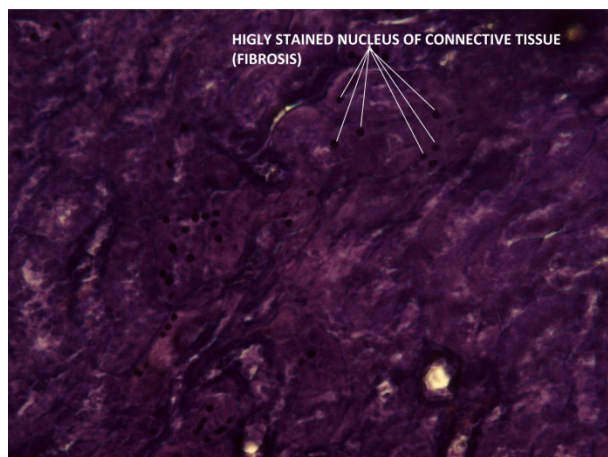


Figure-8
Heart sample 0.7



Figure-9
Heart sample 0.7

Kidney: On studying the cross sections of kidney of the rats administered with gradually increasing doses of sodium thiopental it is observed that the cellular structures showed no observable change.

Heart: On studying the cross sections of heart of the rats administered with gradually increasing doses of sodium thiopental, some damage to the tissues was observed depicting fibrosis. Increased connective tissue damage can be seen. Light areas between the heart muscles show the area that has been damaged and repaired by replacing with connective tissue. This type of repair is expected to take place over a period of 4-5 weeks.

Conclusion

The treated kidney tissues showed no observable histological changes. Kidney is a very resilient organ. Drugs that have specific kidney toxicity only tend to adversely affect the organ. Studies have proved that the drug Sodium Thiopental is metabolized in the liver into pentobarbital, 5-ethyl-5-(1'-methyl-3'-hydroxybutyl)-2-thiobarbituric acid and 5-ethyl-5-(1'-methyl-3'-carboxypropyl)-2-thiobarbituric acid. Kidney being the later of the organs to get exposed to the drug could be the reason why no changes were observed.

However, pronounced changes were seen in treated heart tissues. The presence of highly stained nucleus of the connective fibre indicates the replacement of damages heart muscles by connective tissue. The lightly stained area in pictures for heart samples labelled 0.9 and 0.7 shows fibrosis which is prominently visible in rats given the dose 0.7 and 0.9 mg/ml of Sodium thiopental.

This paper studied the effects of Sodium thiopental in albino rats to check for any damages that occurred at histological levels. Not only is narco-analysis a technique that doesn't produce results that are reproducible and consistent, also it is a technique that causes harm.

References

1. Bashir R K., Raman S., Knott J V., Bulmer D R., and Hurtig B J., Influence of Alcohol and Tobacco Use on Sodium Thiopental Requirements in General Anesthesia *Can Fam Physician.* **27(2)** 229–235 (1981)
2. Bennetts FE, Thiopentone Anaesthesia at Pearl Harbour (<http://bj.oxfordjournals.org/cgi/pmidlookup?view=longan&pmid=7547061>) (2012)
3. Bory C., Chantin, Cand Boulieu, RI. Use of thiopental in man, Determination of this drug and its metabolites in plasma and urine by liquid phase chromatography and mass spectrometry, *C. R. Acad. Sci. III, Sci.*, **303(1)**, (1986)
4. Haws J.L., Herman H., Clark Y., Bjoraker R., and Jones D., The chemical stability and sterility of sodium thiopental after preparation. Department of Anesthesiology, Witford Hall Medical Center Lackland Air Force Base, Texas, USA, *A and A*, **86(1)**, 208-213 (1998)
5. Morgan D.J., Blackman G.L., Paull J.D. and Wolf L.J., Pharmacokinetics and plasma binding of thiopental, *Anesthesiology*, **54 (6)**, 474–480 (1981)
6. Pearlman T., Behavioral desensitization of phobic anxiety using thiopental sodium, *The American Journal of Psychiatry* 1580–1582 (1980).
7. Pereda J., Gómez-Cambronero L. and Alberola A., Co-administration of pentoxifylline and thiopental causes death by acute pulmonary oedema in rats. *Br. J. Pharmacol*, **149(4)**, 450–5 (2006)
8. Rappaport M.A., Hiraki Y.G., Rosenfeld B., Cowan R.C., and Lang J., Effect of Autoperfusion of the Liver on Detoxication of Thiopental Sodium University of Toronto, Toronto, Canada, 193-198, (1956)
9. Truth serum used on 'serial child killers, Sydney Morning Herald, Reuters (2007)
10. Turcant, Alain. Delhumeau, Alain. Premel-Cabic, Anne, Granry, Jean-Claude Cottineau, Christian, Patrick, Allain and Pierre, Thiopental Pharmacokinetics under Conditions of Long-term Infusion (C) American Society of Anesthesiologists, Inc. (1985)
11. Winters W.D., Spector, E., Wallach D.P. and Shidman F.E., Metabolism of thiopental-S35 and thiopental-2-C14 by a rat liver mince and identification of pentobarbital as a major metabolite, *J. Pharmacol. Exp. Ther.*, **114 (3)**, 343–57 (1955)
12. Calhoun N.R., and Truant P.A., The effects of multiple injections of thiopental sodium on the sleeping time and the physiologic disposition of the drug in male rat, **10(11)**, 1183-1191 (1957)