



Effects of an Organophosphate Pesticide, Malathion (50% E.C) on the Liver of air breathing fish, *Heteropneustes fossilis*

Barbhuiya Hasina Begum* and Dey Mithra

Department of Ecology and Environmental Science, Assam University, Silchar-788011, Assam, INDIA

Available online at: www.isca.in, www.isca.me

Received 26th May 2015, revised 30th June 2015, accepted 6th July 2015

Abstract

In the present study histological alterations in the liver of *Heteropneustes fossilis* was studied after exposure to malathion. Fishes were exposed to 1.07ppm (1/10th of 96h LC₅₀) concentration of malathion. The experiment was maintained for 21 days. Light microscopic study of liver of the treated fishes showed haemorrhage, formation of vacuoles and appearance of macrophages. Degeneration of hepatocytes and fibrous tissue invaded with some inflammatory cells were also observed in malathion treated liver of *Heteropneustes fossilis*.

Keywords: Malathion, *Heteropneustes fossilis*, liver, histological alteration.

Introduction

Pesticides are extensively used throughout the world for pest control. Among the different types of pesticides organophosphates have become one of the widely used classes of insecticides. These types of insecticides have low solubility and also degrade very rapidly. Because of this reason exposure of aquatic organisms to organophosphates is difficult to assess. But such insecticides are highly toxic to aquatic organisms and therefore monitoring the impact of these insecticides is essential¹.

In aquatic toxicology, fish plays an important role in toxicity testing and hazard evaluation, as do the white rat and guinea pig in mammalian toxicology². Pesticidal pollution not only has adverse effects on fish production but it also constitutes the most dangerous health hazard. Fishes are quite sensitive to a wide variety of toxicants and are used as indicator of pollution in water-quality management³.

Toxicants impair both the metabolic and physiological activities of the organisms. But only physiological studies are not sufficient for the complete understanding of pathological conditions of tissues under the stress of toxicants. Hence it is essential to have an insight into histological analysis. The severity of tissue damage is a consequence of the concentration of toxicant and it is time dependent. Tissue damage is also related to the toxic potentiality of a particular compound or pesticide accumulated in the tissues⁴. Histopathological changes are widely used as biomarkers in the evaluation of the effect of contaminants on fish health both in the laboratory^{5,6} and field studies^{7,8}. Such type of biomarker not only allows examining specific target organs which are responsible for vital functions⁹ but also provides information regarding to the damage of animal health¹⁰.

Material and Methods

Live specimens of *Heteropneustes fossilis* (10-12 cm in length and 4-6 gm in weight) were collected locally. Fishes were washed with 0.5% KMnO₄ solution for five minutes to remove any external infections and then acclimatized under laboratory condition for a period of 15 days prior to experiment. The physico-chemical characteristics of water which was used for the experiment were pH 6.4±0.04, dissolved oxygen 7.8±0.32mg/l and temperature 28±0.47°C. Commercial fish food was given to fishes during acclimatization. Water of the aquarium was changed daily. The dead fishes were removed immediately.

For histological study 1.07 ppm concentration of malathion was taken which was the 1/10th concentration of 96h LC₅₀ value of malathion. The experiment was continued for 21 days. Ten fishes with replicate were maintained in test solution along with control. During the experiment fishes were fed once a day and uneaten food was removed 30mins after feeding. After 21 days both the control and pesticide treated fishes were sacrificed for histological study. Liver was dissected and kept in formaldehyde for 24 h, then dehydrated, embedded in paraffin and sections were cut at 5 µm thickness and stained with haematoxylin and eosin. Slides were viewed under Olympus CX41 microscope (X100) and photographs were taken.

Results and Discussion

The organ which is associated with the detoxification process and biomarker process is the liver. Because of function, position and blood supply this organ is also one of the most affected organ by contaminants in water¹¹. The liver is susceptible to a number of toxicants and serves as an index to toxicity of surrounding water¹². Liver is the main storage and central metabolizing organ that plays a dual role of secretion of

digestive enzymes and as storage organ for nutrients¹³. Histological observation of liver from control fish in the present study showed normal homogenous mass of hepatocytes with no abnormalities. Sinusoids and central vein were systematically arranged. (figure-1 and figure-2). After treatment with malathion the liver of *Heteropneustes fossilis* showed several pathological alterations. In the present study malathion induced haemorrhage (figure-3) in the liver of *Heteropneustes fossilis*. Break down of blood vessels may result in haemorrhagic area. This type of finding was reported by many authors after toxicant exposure. Haloi *et al.*¹⁴ found haemorrhage in the endosulfan treated liver of *Channa punctatus*. Ganesan *et al.*¹⁵ studied the histopathological impact of sublethal concentrations of 1, 2 dichlorobenzene on the liver of *Catla catla* and reported similar observation. Formation of vacuoles (figure-4) was one of the common alteration in the malathion treated liver. This is probably due to metabolic damage related to exposure with pesticide contaminated water¹⁶. This finding is in agreement with Ba-Omar *et al.*¹⁷.

The histopathological appearance of liver of *Tilapia zillii* exposed to aluminum also showed cytoplasmic vacuolization which was studied by Hadi and Alwan¹⁸. Vacuoles in cytoplasm of liver tissue of *Oncorhynchus mykiss* was also observed by Velisek *et al.*¹⁹ after exposure to bifenthrin. Appearance of macrophages (figure-5) were also observed in the present study. Doaa and Hanan²⁰ reported macrophages aggregation in lead treated liver of *Oreochromis niloticus*. The macrophages usually take up scavenger molecules. Scavenger materials are degraded within the vacuoles of macrophage and reused in the synthesis of new substances^{21,22}. In the present study malathion induced degeneration of hepatocytes (figure-6) in the liver of *Heteropneustes fossilis*.

This finding is in agreement with Muthukumaravel *et al.*²³ who studied histopathological impact of monocrotophos on the liver of *Labeo rohita*. Degenerating hepatocytes were also reported by Ahmed *et al.*²⁴ in cadmium chloride treated liver of *Clarias batrachus*. Fibrous tissue invaded with some inflammatory cells (figure-7) was also observed in the present study.

According to Kadry *et al.*²⁵ atrazine also resulted in similar pathological alteration in the liver of *Clarias gariepinus*.

Conclusion

From the present study it can be concluded that sub lethal concentration of malathion resulted in a large number of histopathological alterations in the liver of fish which is a non target and economically important organism. Liver perform many important functions like detoxification, metabolism and secretion of digestive enzymes. It also acts as a storage organ of essential nutrients. So, histopathological alterations like haemorrhage, formation of vacuoles appearance of macrophages, degeneration of hepatocytes etc. as observed in the present study can result in metabolic disturbances. Such disturbance can have an adverse effect on fish health.

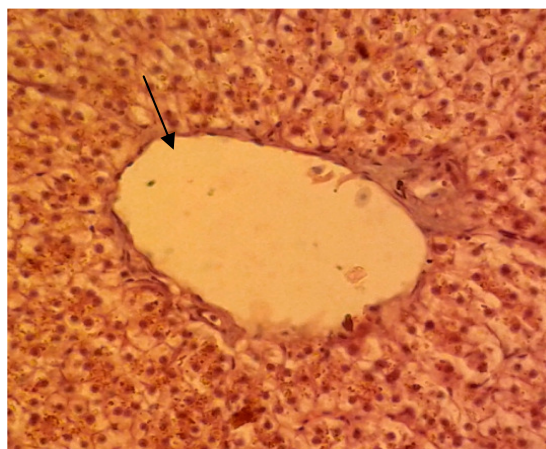

Figure-1
Control liver showing central vein (100X)

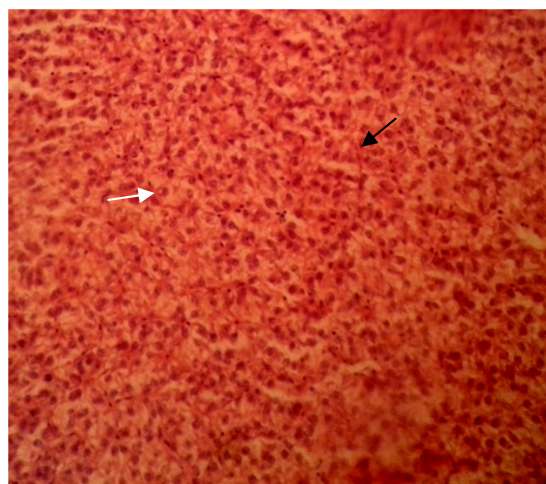


Figure-2
Control liver showing hepatocytes (white arrow) and sinusoids (black arrow) (100X)

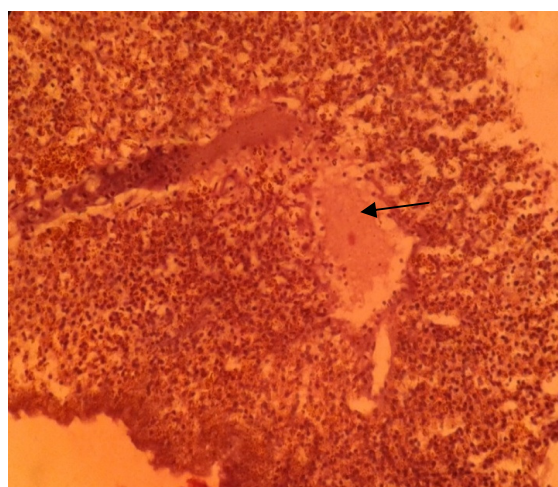


Figure-3
Malathion treated liver showing haemorrhage (100X)

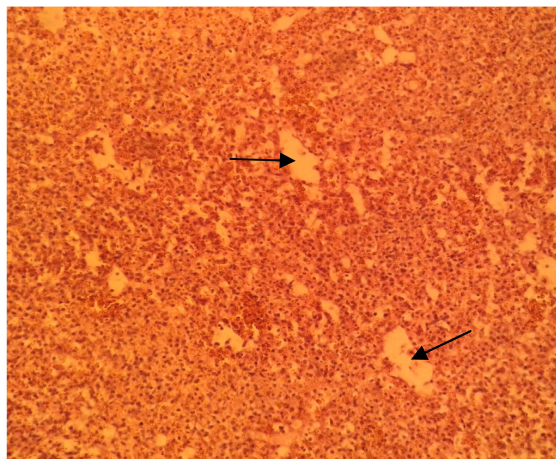


Figure-4

Malathion treated liver showing formation of vacuoles (100X)

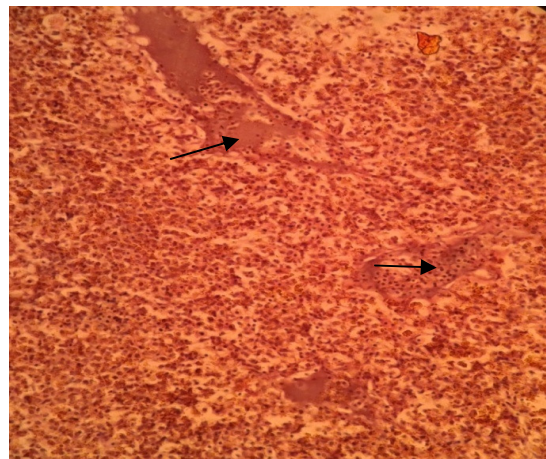


Figure-7

Malathion treated liver showing fibrous tissue invaded with some inflammatory cells (100X)

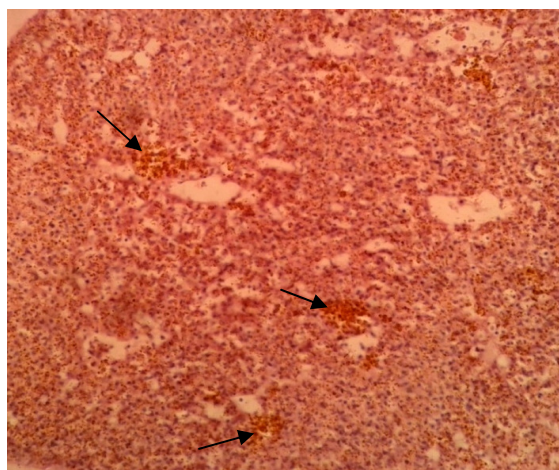


Figure-5

Malathion treated liver showing appearance of macrophages (100X)

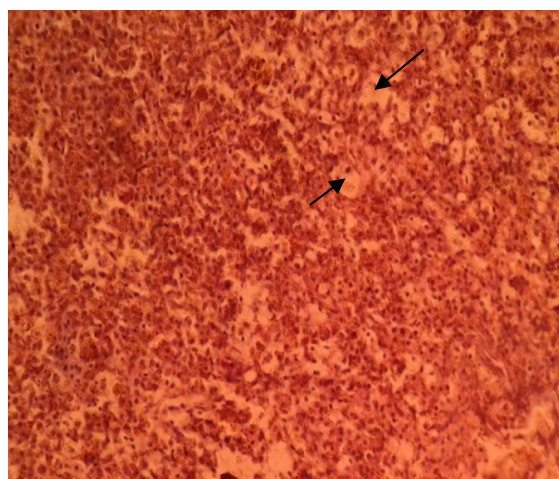


Figure-6

Malathion treated liver showing degeneration of hepatocytes (100X)

Acknowledgement

Authors are grateful to University Grant Commission (UGC), New Delhi, India for the fellowship.

References

1. Halappa R and David M, Behavioural responses of the freshwater fish, *Cyprinus carpio* (Linnaeus) following sublethal exposure to chlorpyrifos, *Turk. J. Fish. Aquat. Sci.*, **9**, 233-238 (2009)
2. Annon, EPA bans most DDT uses, readies lead action, *Environ Sci Technol.*, **6**, 675 (1972)
3. Bantu N. and Vakita V.R., Acute toxicity of chlorantraniliprole to freshwater fish *Channa punctatus* (Bloch), *Adv. in Zool and Botany*, **1(4)**, 78-82 (2013)
4. Jayantha R.K., Histopathology as a diagnostic tool in evaluating of toxicity, Environmental Toxicology, Selected Lectures and Methods, S.V. University, Tirupati, India (1984)
5. Wester P.W. and Canton J.H., The usefulness of histopathology in aquatic toxicity studies, *Comp. Biochem. Physiol.*, **100**, 115-117 (1991)
6. Thophon S., Kruatrachue M., Upatham E.S., Pokethiriyook P., Sahaphong S. and Jaritkhuan S., Histopathological alterations of white seabass, *Lates calcarifer*, in acute and subchronic cadmium exposure, *Environ. Pollut.*, **121**, 307-320 (2003)
7. Hinton D.E., Baumann P.C., Gardner G.R., Hawkins W.E., Hendricks J.D., Hoque R.A., M.J.A. Mirja, M.M. and Miah M.S., Toxicity of diazinon and sumithion to *Puntius gonionotus*, *Bangladesh J. Tran. Dev.*, **6(1)**, 19-26 (1993)
8. Teh S.J., Adams S.M. and Hinton D.E.,

- Histopathological biomarkers in feral freshwater fish populations exposed to different types of contaminant stress, *Aquatic Toxicol.*, **37**, 51-70 (1997)
9. Gernhofer M., Pawet M., Schramm M., Muller E. and Triebkorn R., Ultrastructural biomarkers as tools to characterize the health status of fish in contaminated streams, *J. Aquat. Ecosyst. Stress and Recovery*, **8**, 241-260 (2001)
 10. Hinton D.E. and Lauren D.J., Liver structural alterations accompanying chronic toxicity in fishes: potential biomarkers of exposure. In: McCarthy, J.F. and Shugart L.R. (Eds.), *Biomarkers of Environmental Contamination*, Boca Raton, Lewis Publishers, 51-65 (1993)
 11. Camargo M.M. and Martinez C.B., Histopathology of gills, kidney and liver of a Neotropical fish caged in an urban stream, *Neotro. Ichthyol.*, **5**, 327-336 (2007)
 12. Singh S. and Shrivastava N., Histopathological changes in the liver of the fish *Nandus nandus* exposed to endosulfan and carbaryl, *J. Ecotoxicol. Environ. Monit.*, **8**(2), 139-144 (1998)
 13. Reddy S.J., Cadmium effect on histobiomarkers and melanomacrophage centers in liver and kidney of *Cyprinus carpio*, *World J. of Fish and Marine Sci.*, **4** (2), 179-184 (2012)
 14. Haloi K., Kalita M., Nath R. and Borkotoki A., A study on histopathological impact of endosulfan on liver of *Channa punctatus* Bloch, *Int. J. of Res. in Zool.*, **4**(2), 19-23 (2014)
 15. Ganesan N., Kantha Deivi Arunachalam G.N. and Ganapthy S., Histopathological effects of sub lethal exposure to 1, 2-dichlorobenzene on gills and liver of *Catla catla* (hamilton), *Int. J. of Rec Scient. Res.*, **4**(9), 1444-1448 (2013)
 16. Devi Y. and Mishra A., Histopathological alterations in gill and liver anatomy of fresh water, air breathing fish *Channa punctatus* after pesticide Hilban® (chlorpyrifos) treatment, *Adv. Biores.*, **4**(2), 57-62 (2013)
 17. Ba Omar T.A., Al-Kharusi I. and Victor R., Effects of pesticide temephos on the liver of *Aphanius dispar* (Ruppell 1828) (Pisces: Cyprinodontidae): A microscopic study, *J. for Sci.*, **18**, 11-18 (2013)
 18. Hadi A.A. and Alwan S.F., Histopathological changes in gills, liver and kidney of fresh water fish, *Tilapia zillii*, exposed to aluminum, *Int. J. of Pharm. and Life Sci.*, **3**(11), 2071-2081 (2012)
 19. Velisek J., Svobodova Z. and Piackova V., Effects of acute exposure to bifenthrin on some haematological, biochemical and histopathological parameters of rainbow trout (*Oncorhynchus mykiss*) *VETMED*, **54**(3), 131-137 (2009)
 20. Doaa M.M. and Hanan H.A.E., Histological changes in selected organs of *Oreochromis niloticus* exposed to doses of lead acetate, *J. Life Sci. Biomed.*, **3**(3), 256-263 (2013)
 21. Agius C. and Roberts R.J., Melano-macrophage centers and their role in fish pathology, *J. Fish. Dis.*, **26**(9), 499-509 (2003)
 22. Passantino L., Cianciotta A., Jirillo F., Carassi M., Jirillo E. and Passantino G.F., Lymphoreticular system in fish: erythrocyte-mediated immunomodulation of macrophages contributes to the formation of melanomacrophage centers. *Immunopharm. Immunotoxicol.*, **27**, 147-61 (2005)
 23. Muthukumaravel K., Rajaraman P., Nathiya N., Govindarajan M. and Raveendran S., Studies on the histopathology of selected organs of freshwater fish *Labeo rohita* exposed to pesticides monocrotophos, *Int. J. of Recent Scientific Res.* **4** (11), 1728-1735 (2013)
 24. Ahmad B., Qureshi T.A., Manohar S., Kaur P. and Khaliq R., Effect of cadmium chloride on the histoarchitecture of liver and kidney of a freshwater catfish, *Clarias batrachus*, *Int. J. of Env. Sc.*, **2**(2), 531-536 (2011)
 25. Kadry S.M., Marzouk M.S., Amer A.M, Hanna M.I, Azmy A.H. and Hamed H.S., Vitamin E as antioxidant in female African catfish (*Clarias gariepinus*) exposed to chronic toxicity of atrazine, *Egypt. J. Aquat. Biol. And Fish*, **16**(2), 83-98 (2012)